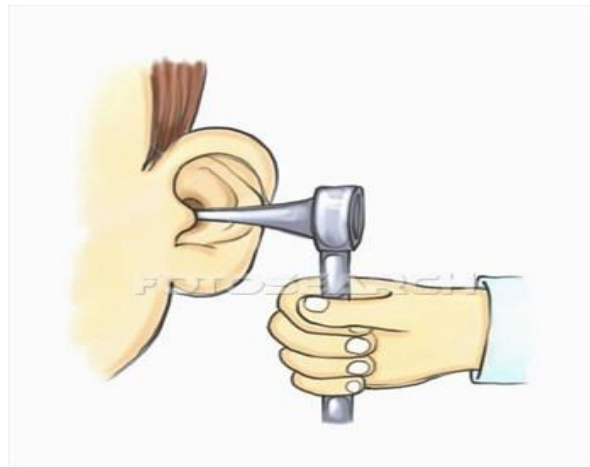

The School Nurse's Guide to Ear Infections



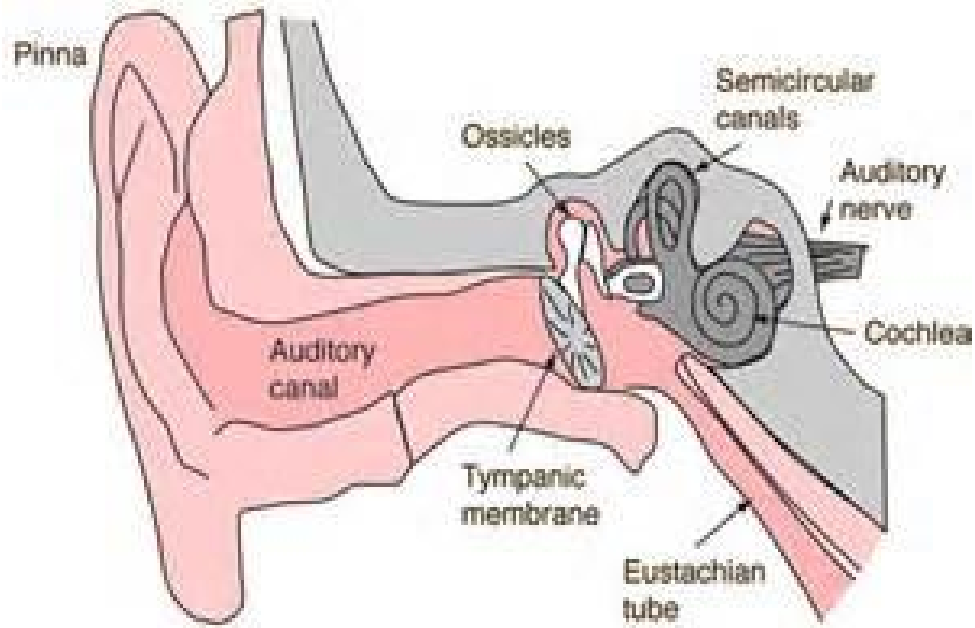
087a2950 www.fotosearch.com

TABLE OF CONTENTS

PAGE:

3. Normal Ear Anatomy and Ventilation
4. Common Terms Associated with Otitis Media
5. What am I Looking at and Healthy Tympanic Membrane
6. Cauliflower Ear; Cholesteatoma
7. Tympanostomy Tube and Types of Tympanostomy Tubes
8. Perforated Tympanic Membrane; Otitis Media
9. Otitis Media with Effusion; Otitis Externa
10. Guidelines for Treatment of Otitis Media; Watchful Waiting
11. Antibiotics
12. Surgery; Ear Tube Placement Post-Surgical Information
13. Common Medications and Common Misconceptions
14. References

Normal Ear Anatomy



Ridenour, J.S., *It's Probably Nothing, An Examination of the Ear* (PowerPoint slides).

Normal ear ventilation

The Eustachian tube provides ventilation of the middle ear. This tube runs to the back of the throat. This end acts like a valve by opening and closing to regulate air pressure in the middle ear, refresh air in the ear and drain normal secretions from the middle ear. An upper respiratory infection or allergies can block the Eustachian tube with mucus, swelling, or inflammation. This can cause an accumulation of fluid in the middle ear. As a child grows, the Eustachian tube becomes flatter so this is less likely to occur. (A Guide to the Middle Ear, 1998, pp1,2,5)

COMMON TERMS ASSOCIATED WITH OTITIS MEDIA

Acute Otitis Media (AOM)-Rapid onset ear infection.

Audiogram-Recorded results of hearing test.

Bilateral Myringotomy with Tubes (BMT)-Surgery to place tubes in both ears.

Chronic Hearing Loss (CHL)-Hearing loss documented by audiogram over continuous amount of time.

Chronic Otitis Media with Effusion (COME): Chronic ear infection with fluid.

Myringotomy-The incision made in the tympanic membrane

Otolaryngologist-Doctor trained to evaluate disorders of the Ears, Nose and Throat (ENT).

Otorrhea-Ear drainage.

Otalgia-Ear pain.

Pressure Equalization Tubes (PET)-Tubes that are placed in the tympanic membrane after myringotomy.

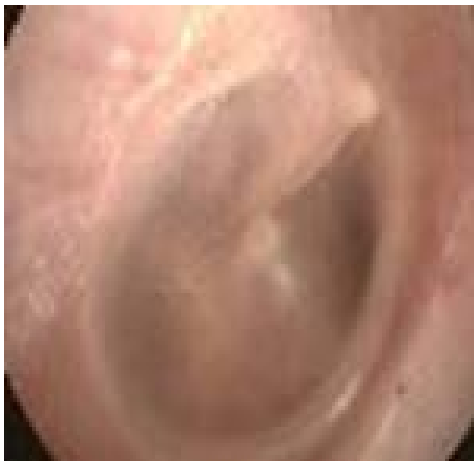Recurrent Acute Otitis Media (RAOM)-Ear infections that occur repeatedly even with treatment.

Tympanometry-A way to measure ear canal pressure. Can help determine if ear tubes are patent and functioning

What am I looking at?

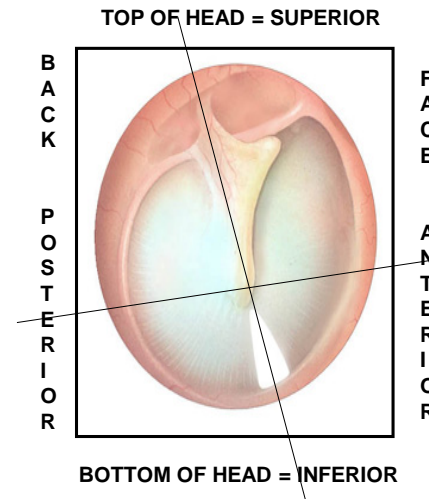
Examining a child's ear with an otoscope is common practice for school nurses but unfortunately it may have been several years since a new school nurse has done this. The following pictures help provide some information as to what you are looking at when you look in a child's ear with an otoscope.

HEALTHY TYMPANIC MEMBRANE



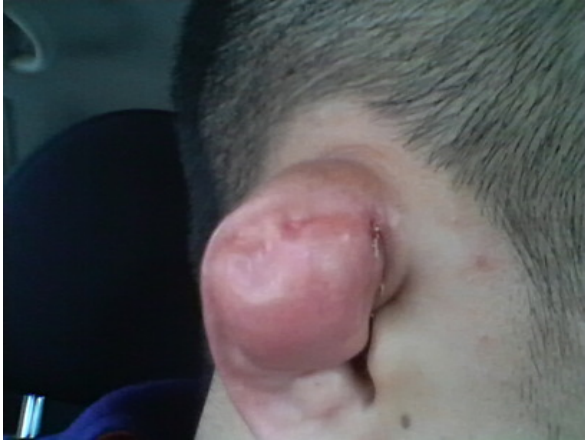Kavanaugh, Catherine. *Normal Eardrums (Tympanic Membranes)*. Digital image. *Normal Eardrum*. July 2015.

Tips on Examining the Ear



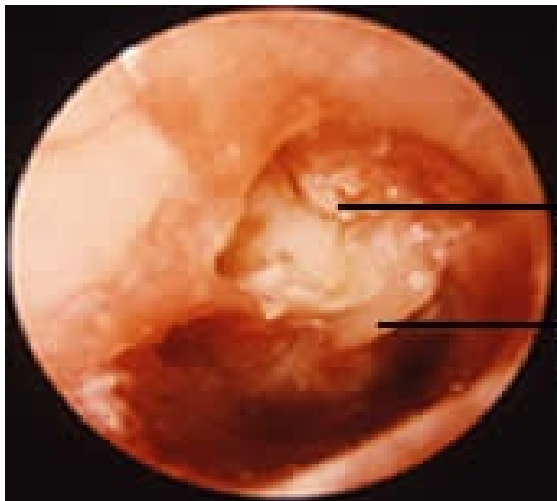
Ridenour, J.S., *It's Probably Nothing, An Examination of the Ear (PowerPoint slides)*.

CAULIFLOWER EAR



Also known as wrestler's ear or boxer's ear a condition where there is a deformity in the outer ear of a person. This condition shrivels up the ear and causes it to fold within itself and look pale thus giving the ear a cauliflower like appearance. This is where the injury gets its name from. Particular people such as boxers, wrestlers and martial artists are more prone to acquire this type of injury. This condition arises when the ear of that person is struck hard and blood clotting takes place under the skin. In some cases the skin gets cut off from the cartilage, therefore the connection between the skin and cartilage is damaged. Treatment is needed by Otolaryngologist to relieve pressure and remove blood under the skin. Cauliflower ear is prevented by wearing appropriate head gear.

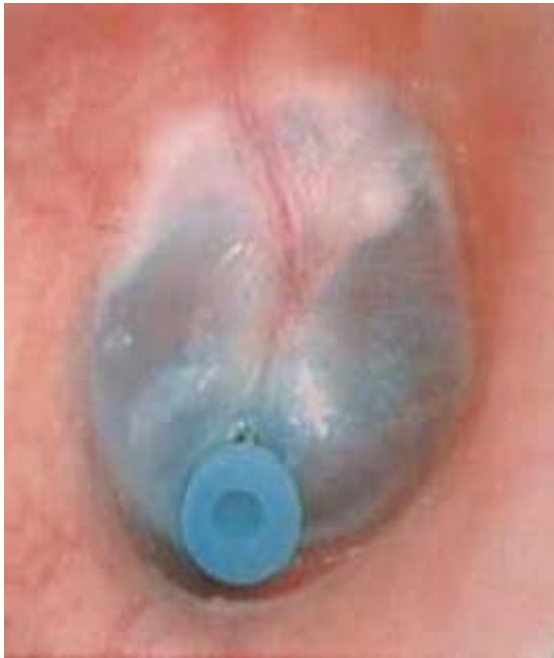Cauliflower Ear Picture. Digital image. *Medical Pictures Info Useful Health Definitions and Pictures.* Medical Pictures Info, 2015. Web. 15 July 2015.



CHOLESTEATOMA

A tumor usually growing in a confined space (such as the middle ear or mastoid) and frequently constituting a sequel to chronic otitis media is called a cholesteatoma. This is a serious condition which requires immediate evaluation from Otolaryngologist and possible surgical intervention.

Cholesteatoma.jpg. Digital image. *Ear Institute of Chicago.* Ear Institute of Chicago, 2015. Web. 15 July 2015.




TYMPANOSTOMY TUBE

Tubes are placed in the tympanic membrane to equalize pressure by venting the middle ear. They are inserted into the tympanic membrane via an incision called myringotomy. After tubes are placed, it is recommended that the child follow up with the ENT surgeon every 6 months. Drainage from the tubes indicates an otitis media. Tubes may stay in place for 1 -3 years and should spontaneously extrude on their own within 3 years. If extrusion does not spontaneously occur, removal under anesthesia may be recommended.

Tubes may become plugged and not work as designed and/or extrude remaining in the ear canal requiring further evaluation and interventions by the pediatrician or Ear, Nose and Throat Specialist. Tubes may need to be replaced if the child continues to have ear infections after tube extrusion or has continued hearing loss. (Rosenfeld, R.M. 2005, pp72- 81)

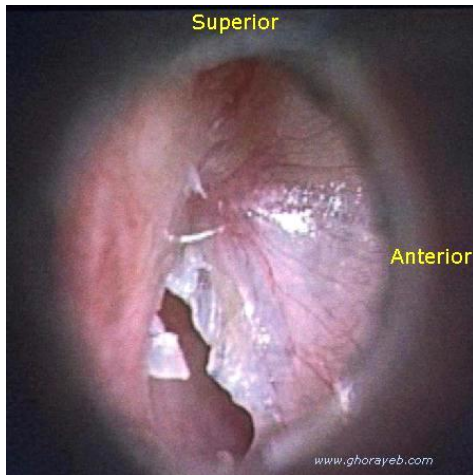
Ridenour, J.S., *It's Probably Nothing, An Examination of the Ear* (PowerPoint slides).



TYPES OF TYMPANOSTOMY TUBES

There are several different types of ear tubes that may vary in size, shape and color. It is important to fully assess and ask caregivers if child has a history of ear tube placement when viewing the ear. It is common for a misdiagnosis of a foreign body by the health professional that is unfamiliar with the variety of ear tubes available.

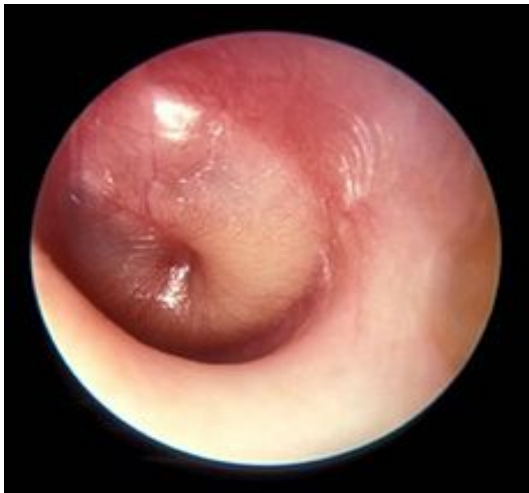Ridenour, J.S., *It's Probably Nothing, An Examination of the Ear* (PowerPoint slides).



PERFORATED TYMPANIC MEMBRANE

If there is a lot of pus in the middle ear, this can cause pressure on the tympanic membrane and cause the membrane to tear or perforate. When this happens, the pain of an earache is usually relieved. There may be drainage from the ear canal of pus and/or blood. Hearing loss can occur with repeated perforations. Usually the ear drum will heal itself after a perforation and hearing will return to baseline; however, if the perforation does not heal, a surgical procedure requiring a paper patch will be performed to aid in the healing process.

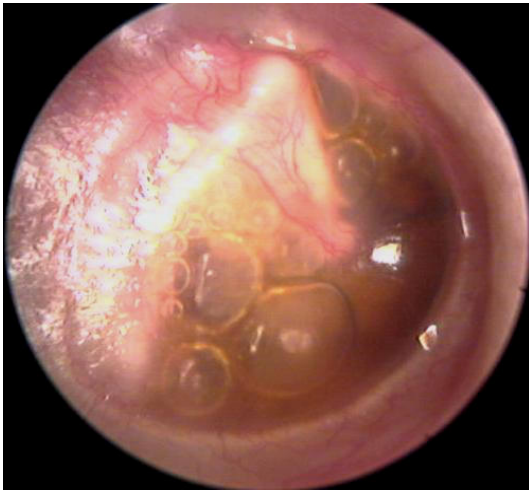Picture of Right Inferior Tympanic Membrane Perforation. Digital image. *Pictures of Tympanic Membrane Perforation.* OTOLARYNGOLOGY HOUSTON, 11 Oct. 2014. Web. 15 July 2015.



OTITIS MEDIA

Otitis media is an infection in the middle ear which may be caused when bacteria or viruses in the nose and/or throat from a cold or upper respiratory infection **move** through the Eustachian tube into the ear. If the Eustachian tube becomes blocked, then the middle ear can fill with pus. This pus buildup results in pain and swelling. The ear drum cannot move as it normally would so there may be a decrease in hearing. There may also be a fever along with other symptoms. (AAOHNS Patient Health Information, website)

OTITIS MEDIA AGUDA FASE DE SUPURACIÓN. Digital image. *OTITIS MEDIA AGUDA: IMÁGENES.* Hawke Library, 2015. Web. 15 July 2015.

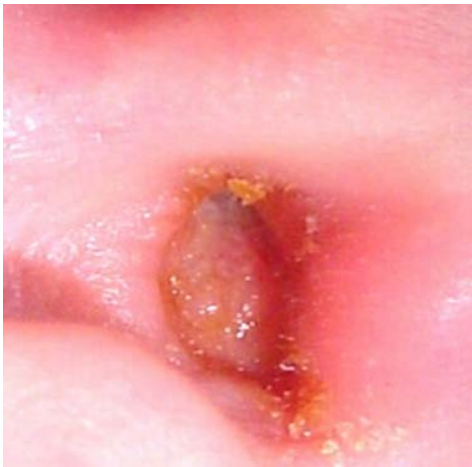


OTITIS MEDIA WITH EFFUSION

Fluid in the ear or ears with buildup in the middle ear space. The fluid may cause problems with hearing and can remain in the middle ear for a long time, possibly leading to ear infections. Untreated effusions can lead to temporary or permanent hearing loss.

(AAOHNS Patient Health Information, website)

Otitis Media.jpg. Digital image. *Medical Pictures Info Useful Health Definitions and Pictures*. Medical Pictures Info, 2015. Web. 15 July 2015.



OTITIS EXTERNA

Also known as **Swimmer's Ear, Otitis Externa** is the swelling of the external ear canal. Typically accompanied by severe ear otalgia, ear itching, foul smelling otorrhea, a feeling that ear is plugged and frequent exposure to swimming. Treatment may include drops for numbing, antibiotic and/or steroid ear drops to reduce **infection and swelling**, Tylenol and Motrin for pain management and discontinuation of swimming until infection clears. Persistent infection not responsive to treatment or swelling behind the ear will warrant re-evaluation by health care provider.

Otitis Externa (Bacterial). Digital image. *Pictures of Otitis Externa (Bacterial)*. Otolaryngology Houston, 25 Apr. 2014. Web. 15 July 2015.

GUIDELINES FOR TREATMENT OF OTITIS MEDIA

The American Academy of Pediatrics (AAP) provides guidelines for treating Otitis Media.

All ages with otorrhea (ear drainage) and Acute Otitis Media or with severe symptoms such as elevated temperature or persistent pain for greater than 48 hours along with Acute Otitis Media should receive antibiotics.

Children under age 2 with bilateral Acute Otitis Media without otorrhea should receive antibiotics, while those older than 2 years of age can also undergo a period of observation or may receive antibiotics. All ages with an ear infection in only one ear can be observed first or may receive antibiotics. (Lieberthal, A. S. et al, AAP practice guidelines 2013.)

Watchful Waiting

The newest AAP guidelines include the recommendations for watchful waiting in some cases. This decision is made based on the clinical status of the patient and after thorough discussion with the parents ensuring they will pursue treatment if pain continues, worsens or the child does not improve within 2-3 days. Sometimes a wait and see prescription (WASP) is provided to the parents so if the infection gets worse, a prescription is already available for an antibiotic. (Lieberthal, A. S. et al AAP Practice Guidelines, 2013)

Antibiotics

The American Academy of Pediatrics also has recommendations for which antibiotics to use.

First line treatment for ear infections is high dose Amoxicillin (80-90 mg/kg divided BID) as long as it has not been received in the past 30 days.

If the ear infection does respond to treatment or recurs before 30 days, Augmentin is the second antibiotic to be prescribed.

Omnicef is the third line of treatment if Augmentin is unsuccessful in treatment of the ear infection.

If ear infection is not responsive to Ominicef, Rocephin may be prescribed Intramuscularly (IM) in 3 doses administered over 3 days; however, this treatment is reserved for the most severe cases of otitis media that have become resistant or unresponsive to other antibiotics. Erythromycin and azithromycin have limited effect against common Acute Otitis Media pathogens. A referral to an ENT specialist for further evaluation is often given for persistent ear infections. (Lieberthal, A. S. 2013)

Surgery

When ear infections occur repeatedly, even with antibiotic treatment, surgery may be considered. The AAP provides guidelines for when tympanostomy tubes are appropriate. The AAP guidelines state surgery may be offered if there are 3 episodes of Otitis Media within 6 months, 4 episodes in 1 year with 1 episode in the preceding 6 months, documented hearing loss or suspected structural abnormalities. Tubes are also considered for children with chronic middle ear effusions defined as having documented middle ear fluid for more than 3 months. Children that have ear infections that cause other issues such as febrile seizures, facial paralysis and speech delays are also candidates for tubes. (Lieberthal, A. S. 2013)

Ear Tube Placement Post-Surgical Information

The actual procedure for placing tubes is very short with very little discomfort. If there was any loss of hearing caused by the fluid buildup, the hearing loss is relieved with the surgery. (AAOHNS, Ear Tubes, 2015) Children that have had balance issues because of middle ear fluid often have an immediate improvement. Post-operative ear drainage may occur after tube placement and is treated with ear drops such as Ciprodex for up to 7 days after surgery. Any time after surgery when ear drainage occurs with patent tubes, ear drops are started and given **twice a day for 7 days**. If the ear drops do not clear up the drainage, then the child needs to be re-evaluated by the provider. Children may return to school within 24 hours after surgery, with consideration to their particular school environment, as determined by the provider. Children may swim in chlorinated pool for depths no greater than 3 feet and shower without need for ear plugs. Lake water or other unclean water sources and depths greater than 3 feet in clean water require the use of ear plugs and possible specialized headband to reduce risk of water entering the ear. (CMH Care Card, 2010)

COMMON MEDICATIONS

Amoxicillin (80-90 mg/kg divided BID)- 1st line oral antibiotic for ear infection

Augmentin- 2nd line oral antibiotic for ear infection

Auralgan- Numbing ear drop used for swimmers ear to decrease pain. **Not for use for patients with ear tubes.**

Ciprodex-Antibiotic and Steroid Ear Drop. May be marked for ophthalmic use, approved for otologic use.

Omnicef- 3rd line oral antibiotic for ear infection

Rocephin- Intramuscularly injected antibiotic reserved for severe ear infections unresponsive to oral antibiotics.

COMMON MISCONCEPTIONS-Helpful information

Parents often believe that having tubes placed will mean their child will not have any further ear infections; however, tubes do not prevent ear infections, they allow the infection to drain so the infection may be treated directly at the source instead of with systemic oral antibiotics. Children with tubes often have many ear infections.

The tube creates an opening into the middle ear so any water that gets in that space can potentially cause infection and pain. Children may swim in chlorinated pool for depths no greater than 3 feet and shower without need for ear plugs. Lake water or other unclean water sources and depths greater than 3 feet in clean water require the use of ear plugs and possible specialized headband to reduce risk of water entering the ear. (CMH Care Card, 2010)

Numbing drops should NEVER be given to a child with tubes in their ears or if you are unsure if the tubes are present and/or patent. If there is a functioning tube, the drops will go into the middle ear space causing pain and potential damage to the middle ear.

REFERENCES:

A Guide to Middle Ear Infections (Otitis Media), a Humanatomy Board Book, 1998 by Tom Peters and company Inc. Gladstone, NJ 07934

American Academy of Otolaryngology – Head and Neck Surgery, www.entnet.org, Ear Tubes Patient Health Information, 2015.

CMH Care Card, Myringotomy with Tube – After Surgery. 2000-2010.

Lieberthal, A. S. et al, *The Diagnosis and Management of Acute Otitis Media, Clinical Practice Guidelines from the American Academy of Pediatrics*. Pediatrics.aappublications.org, published online Feb. 25, 2013, *Pediatrics*: March 1, 2013, Vol. 131 No. 3, pp.e964- e999.

Mayo Clinic Website, Ear Tubes, www.mayoclinic.org/tests-procedures/ear-tubes/basics/why-its-done/pre-20013911

Primary Care Otolaryngology. 2000, American Academy of Otolaryngology – Head and Neck Surgery, Inc, Alexandria, VA

Ridenour, J.S., *It's Probably Nothing, An Examination of the Ear* (PowerPoint slides).

Staffel, Gregory J., Demeny III, James C., Eibling, David E., Johnson, Jonas T., Kenna, Margaret A., Pitman, Karen T., Rosen, Clark A., Thompson, Scott w. Rosenfeld, Richard M., *A Parent's Guide to Ear Tubes*, BC Decker Inc., 2005 Hamilton, Ontario.